

# Dizziness tests and manoeuvres

## Primary Care Management Guidelines for GPs

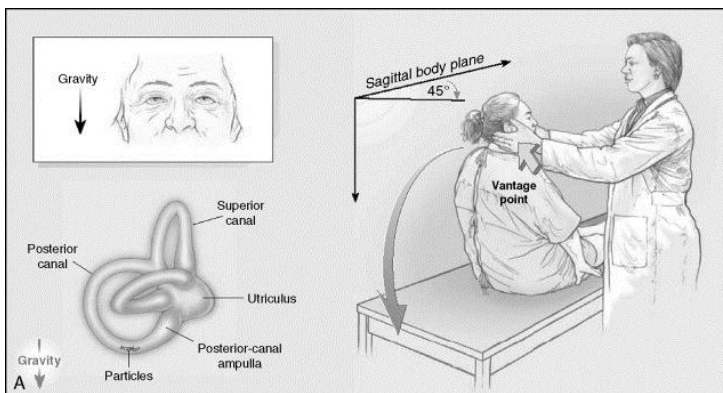
1. Hallpike test.....	1
2. Epley Manoeuvre .....	2
3. Home (Modified) Epley Manoeuvre .....	3
4. Head Impulse Test (HIT) .....	4

### 1. Hallpike test

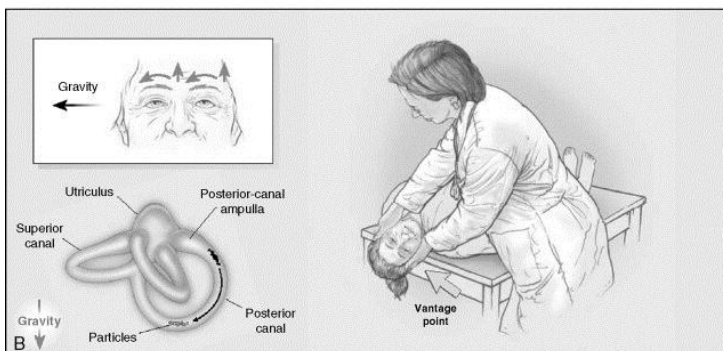
The Hallpike test is utilized to aid in the diagnosis of benign paroxysmal positional vertigo (BPPV). It may also be useful in provoking other forms nystagmus, including that indicative of a central pathology - such as down beat nystagmus.

#### How to perform the Hallpike test

<http://ars.els-cdn.com/content/image/1-s2.0-S1567423110090088-gr2.jpg>



The Hallpike test is performed on an examination couch (see video link below) and it is often easier to place a pillow under the patient's shoulders rather than extend their head over the end of the examination couch (particularly where the examination couch is not easily moved).



The most common abnormal finding is that of posterior canal BPPV, in which there is an initial period of latency (i.e. no nystagmus) prior to the onset of the characteristic clockwise torsional (rotational) nystagmus with a lesser upbeat component.

If nystagmus of another type is elicited or only subjective dizziness is experienced (i.e. no abnormal nystagmus) then BPPV *cannot* be diagnosed. The test has very good utility even in the presence of limitations such as restricted spinal extension as it is often the *positioning* not the final *position* that provokes the nystagmus.

### Instructional videos:

How to perform the Hallpike Manoeuvre (remember to reverse sides if the other ear is affected):  
<http://www.neurology.org/content/70/22/2067/suppl/DC2> and select "video 1"

A demonstration of the nystagmus seen in a positive Hallpike test:  
<http://www.dizziness-and-balance.com/disorders/bppv/movies/bppv.avi>

Animation of otoconia being displaced into posterior canal:  
<http://www.dizziness-and-balance.com/disorders/bppv/movies/Debris-Redistribution.gif>

## 2. Epley Manoeuvre

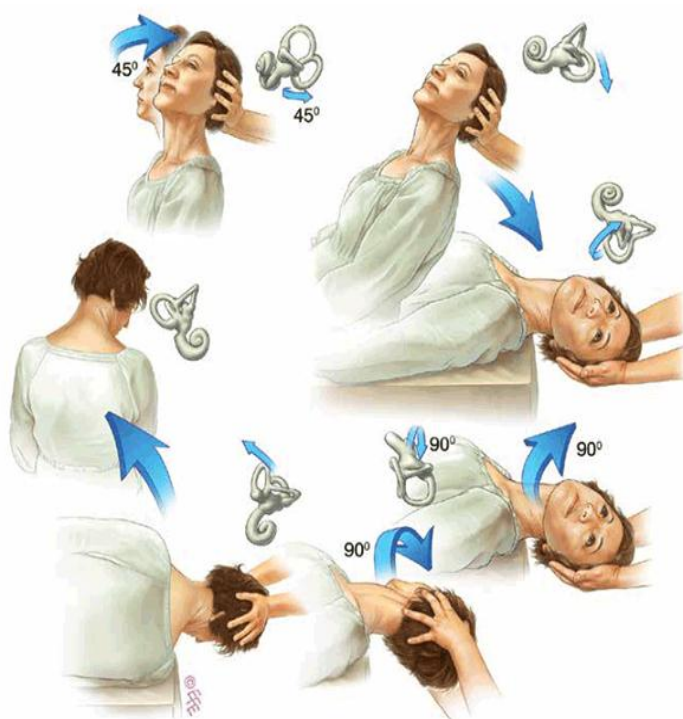The Epley Manoeuvre is a particle repositioning manoeuvre that uses gravity to relocate free floating particles in the semicircular canal, back into the utricle which relieves vertigo in 80% of benign paroxysmal positional vertigo (BPPV) cases.

### How to perform the Epley Manoeuvre:

<http://www.racgp.org.au/download/Documents/AFP/2013/January/February/201301handi.pdf>

The Epley Manoeuvre is generally carried out as a continuation of the Hallpike test.

1. The first two steps are identical to the Hallpike test. From the position in which the positive Hallpike test has been elicited, the patient's head is rotated 90 degrees for 20-30 seconds



2. Another 90 degree head rotation is performed as the patient rolls onto their side, and held for 20-30 seconds. The doctor should control the position of the patient's head as the natural inclination is often to raise the head prior to rotating it and this may disturb the canalith repositioning. In this position the patient is looking down onto the top of the examination couch, and further nystagmus and vertigo may be experienced, so reassurance may be warranted.

3. The final phase is for the patient to lower their legs over the edge of the couch and sit up sideways for 30 seconds. It is important to be prepared that the patient may feel transiently more dizzy following the Epley Maneuver and should be counseled to wait before leaving the surgery.

## Instructional video:

<http://www.neurology.org/content/70/22/2067/suppl/DC2> and select "video 4"

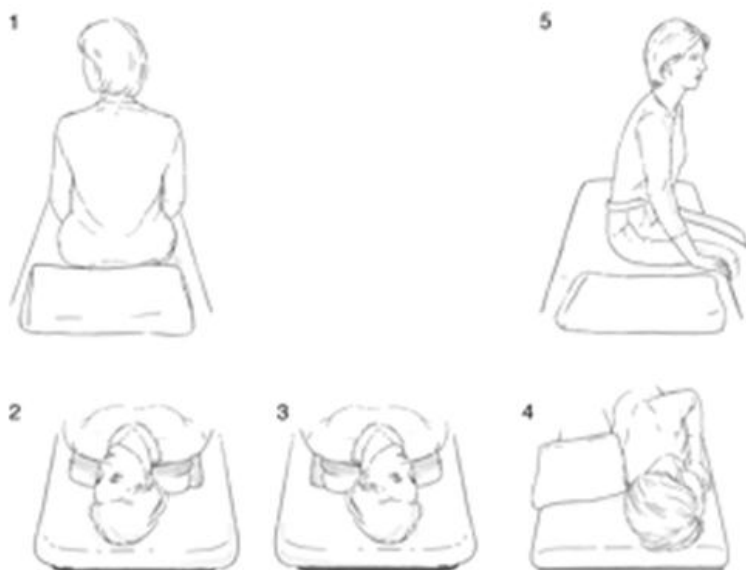
\*Remember to reverse sides if other ear effected.

## 3. Home (Modified) Epley Manoeuvre

The modified Epley Manoeuvre is the preferred particle repositioning manoeuvre that is given to patients with posterior canal BPPV to perform at home. Note that posterior canal BPPV accounts for approximately 90% of BPPV cases.

### Patient instructional hand-out:

Refer to <http://www.neurology.org/content/63/1/150/F1.expansion.html> to download a PowerPoint slide of the following instructions:



These instructions are for the Modified Epley procedure (MEP) for left ear posterior canal benign paroxysmal positional vertigo (PC-BPPV). For right ear BPPV, the procedure has to be performed in the opposite direction, starting with the head turned to the right side:

1. Start by sitting on a bed with your head turned 45° to the left. Place a pillow behind you so that on lying back it will be under your shoulders.
2. Lie back quickly with shoulders on the pillow, neck extended, and head resting on the bed. In this position, the affected (left) ear is underneath. Wait for 30 seconds.
3. Turn your head 90° to the right (without raising it), and wait again for 30 seconds.
4. Turn your body and head another 90° to the right, and wait for another 30 seconds.
5. Sit up on the right side. This maneuver should be performed three times a day. Repeat this daily until you are free from positional vertigo for 24 hours.

## Instructional video:

\*Remember to reverse sides if the other ear effected.

<http://www.neurology.org/content/suppl/2004/07/26/63.1.150.DC1/video2.mpg>.

## 4. Head Impulse Test (HIT)

The head impulse test is utilized to detect a peripheral vestibular deficit. The patient is instructed to look at an earth fixed target, generally at a 'spot' between the doctor's eyes, while the doctor firmly holds the patient's head and after ensuring they can easily rotate the patient's head from side-to-side performs a short range (amplitude), unpredictable and high acceleration head impulse to the left and right.

In the normal case, the patient is able to maintain visual fixation on the target throughout the test, whilst in the patient with a peripheral vestibulopathy, the eyes are driven with the head off of the target, and the doctor visualizes a corrective saccade (as the patient's eyes move back onto the target). If this occurs with an impulse of the head to the *left*, then it is a *left* sided peripheral vestibulopathy (and visa versa for the right).

### **Instructional videos:**

How to perform the HIT:

[http://www.neurology.org/content/suppl/2009/10/04/73.14.1134.DC2/Video\\_Head\\_Impulse10.mpg](http://www.neurology.org/content/suppl/2009/10/04/73.14.1134.DC2/Video_Head_Impulse10.mpg)